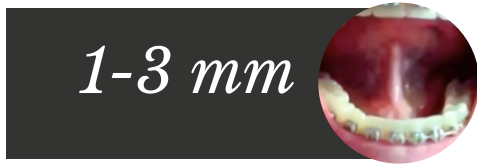

# LINGUAL FRENULUM WOUND HEALING ASSESSMENT SCALE

Authors: Soroush Zaghi, Leyli Norouz-Knutsen, Chad Knutsen, Lesley Kupiec, Loria Nahatis, Richard Baxter

## WHIMS - Wound Healing Integration + Maturation Scale

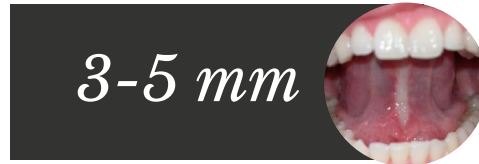### 1. WOUND THICKNESS



1-3 mm

**THIN (SCORE: 2)**

Represents minimal tissue disruption, closely resembling normal healing patterns.



3-5 mm

**MILD/MODERATE (SCORE: 1)**

Indicates moderate tissue involvement, warranting closer observation. Suggesting a moderate-sized wound.

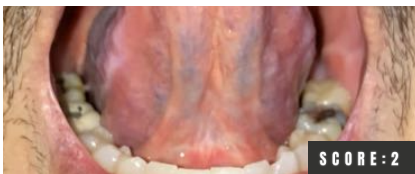

>5 mm

**THICK (SCORE: 0)**

Indicating a larger wound size with extensive tissue involvement. This thickness suggests a potential for complicated healing processes.

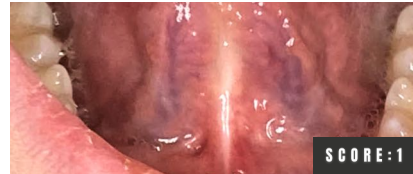
### 2. COLOR DISCREPANCY



SCORE: 2

**WELL INTEGRATED / MATCHING**

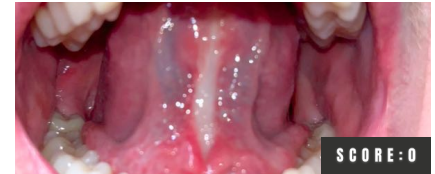Not noticeable / slight color discrepancy between the wound and surrounding tissue, signifying excellent tissue integration.



SCORE: 1

**INTEGRATING / MILD TO MODERATE**

Mild to Moderate color discrepancy with some signs of visible integration.

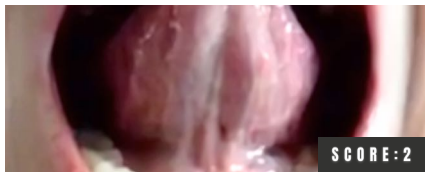

SCORE: 0

**DISTINCT COLOR DISCREPANCY**

Wound appears distinctly white or discolored, contrasts sharply with surrounding tissue

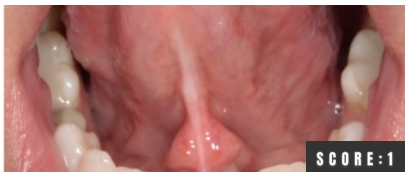### 3. WOUND TEXTURE



SCORE: 2

**SMOOTH / WELL INTEGRATED**

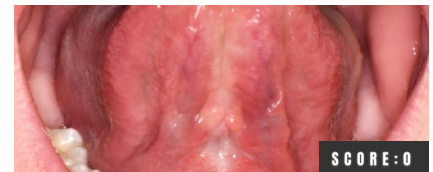Texture is flat and smooth, closely, seamlessly resembling surrounding tissue.



SCORE: 1

**SLIGHTLY RAISED**

Slightly Raised / Irregular, but beginning to blend with adjacent tissue.

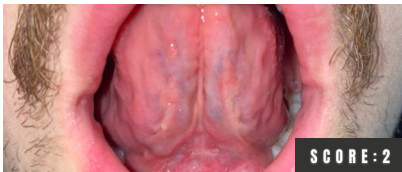


SCORE: 0

**NOTICEABLY ROUGH / IRREGULAR**

Noticeably raised, rough, with irregular contours, noticeably different from the surrounding tissue

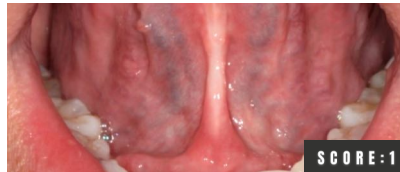### 4. WOUND TIGHTNESS + CONTRACTION



SCORE: 2

**FLEXIBLE / GOOD**

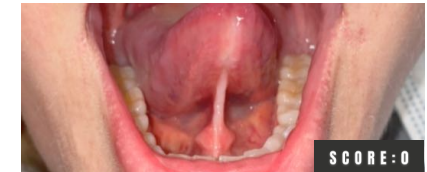The wound is smooth and flexible, similar to adjacent tissue, indicating a relaxed and well-healed tissue.



SCORE: 1

**MILD TO MODERATE TENSION**

Mild to moderate tension observed, indicating ongoing healing but reduced flexibility with some wound constriction.

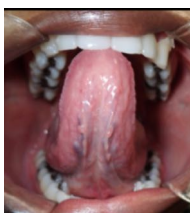

SCORE: 0

**TIGHT / CONTRACTED**

Palpable tension, thicker scar tissue present, tissue feels and appears tight, significantly less flexible than surrounding tissue.

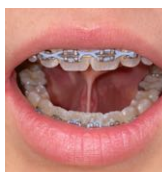### 5. MOBILITY



SCORE: 2

**UNRESTRICTED / GOOD MOBILITY**

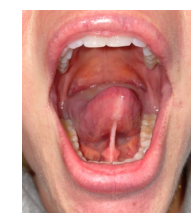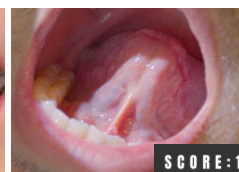Moves easily, without restriction or compensation, mirroring normal mucosal mobility. (Grade 1-2 TRMR)



SCORE: 1

**LIMITED / COMPENSATED MOBILITY**

Limitations in movement, (not severely restricted) exhibiting compensation(s) (Grade 3 compensating to Grade 2 TRMR or with + FOM Hold / DDT)



SCORE: 0

**RESTRICTED MOBILITY**

Severely limited mobility, noticeable restriction compared to normal tissue. (Grade 3/4 TRMR)

### OVERALL GRADING SCALE (0-10)

0-2	Severely Impaired Healing: Indicates critical concerns in almost all aspects of wound healing.
3-4	Significantly Impaired Healing: Shows significant issues in multiple aspects of wound healing.
5-6	Moderately Impaired Healing: Suggests moderate healing challenges.
7-8	Good Healing Progress: Indicates generally good healing with some minor issues.
9-10	Excellent Healing: Reflects optimal wound healing across all categories. Indicates effective treatment and recovery.