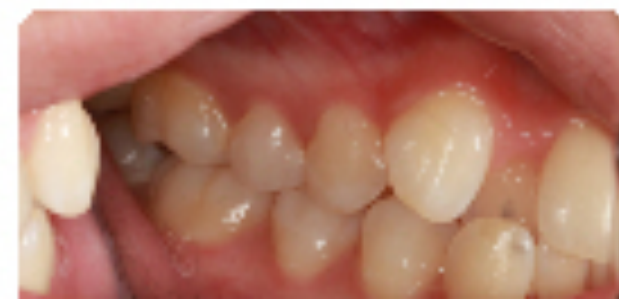
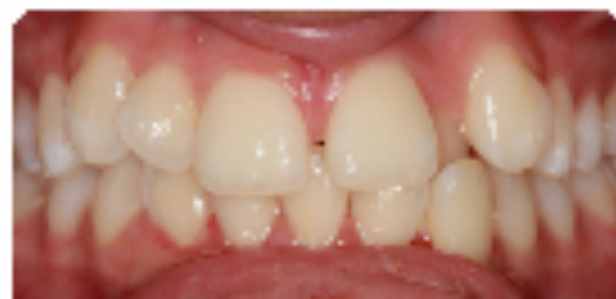
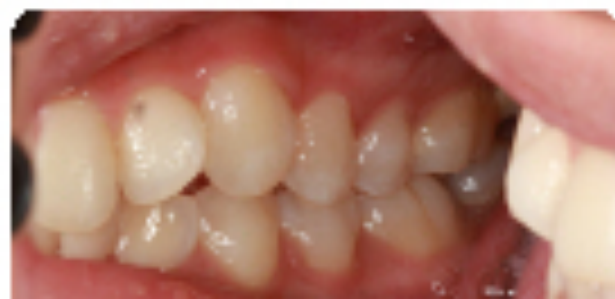
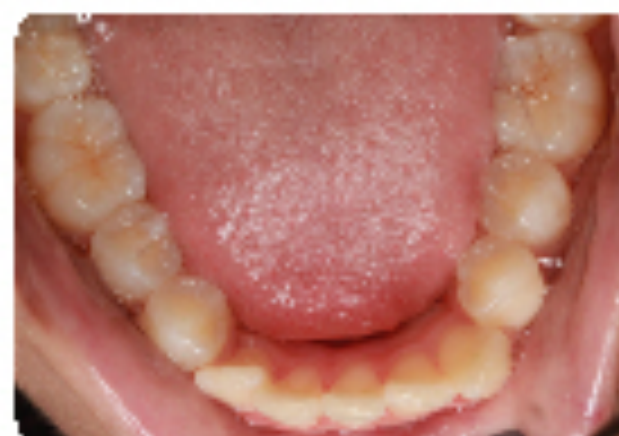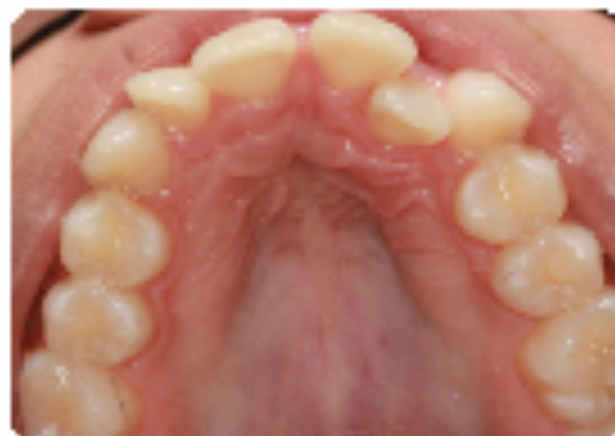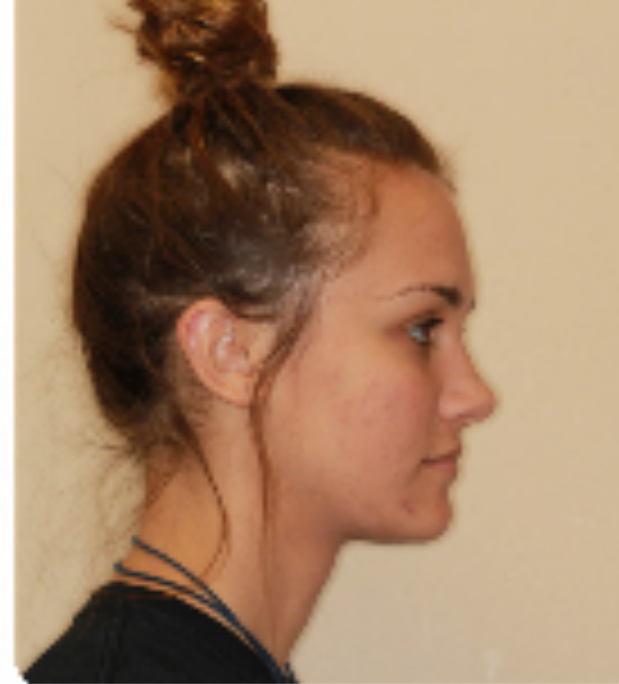Controlled Arch Fixed Guided Growth Appliance

Maxillary Development and Cranial Strain (Asymmetry) Correction

Dr. Stephen Deal

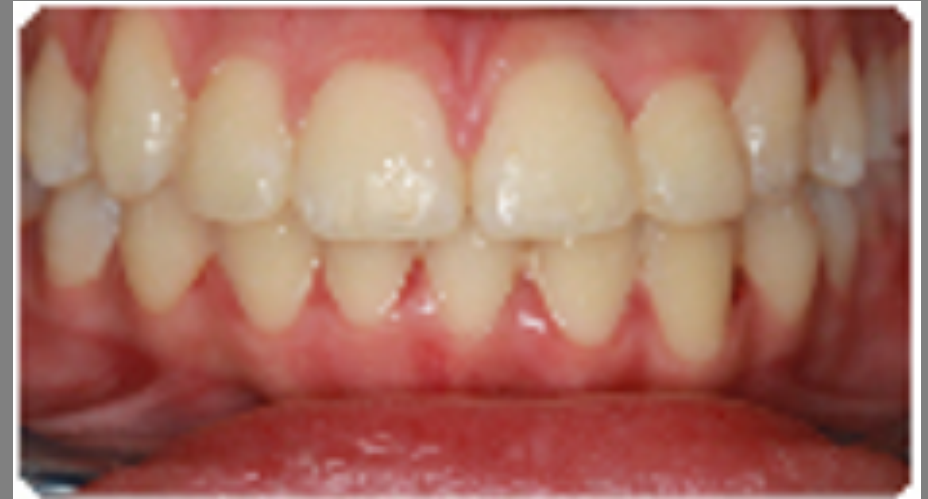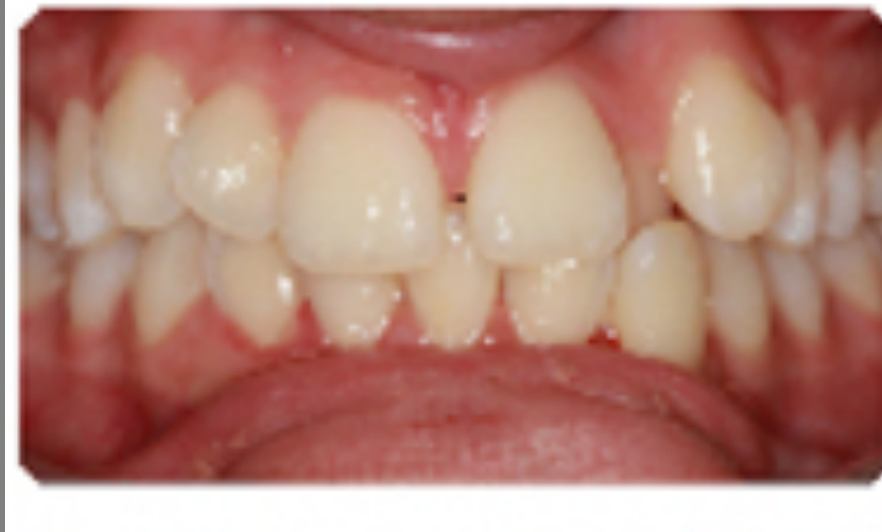DealDDS55@Yahoo.com



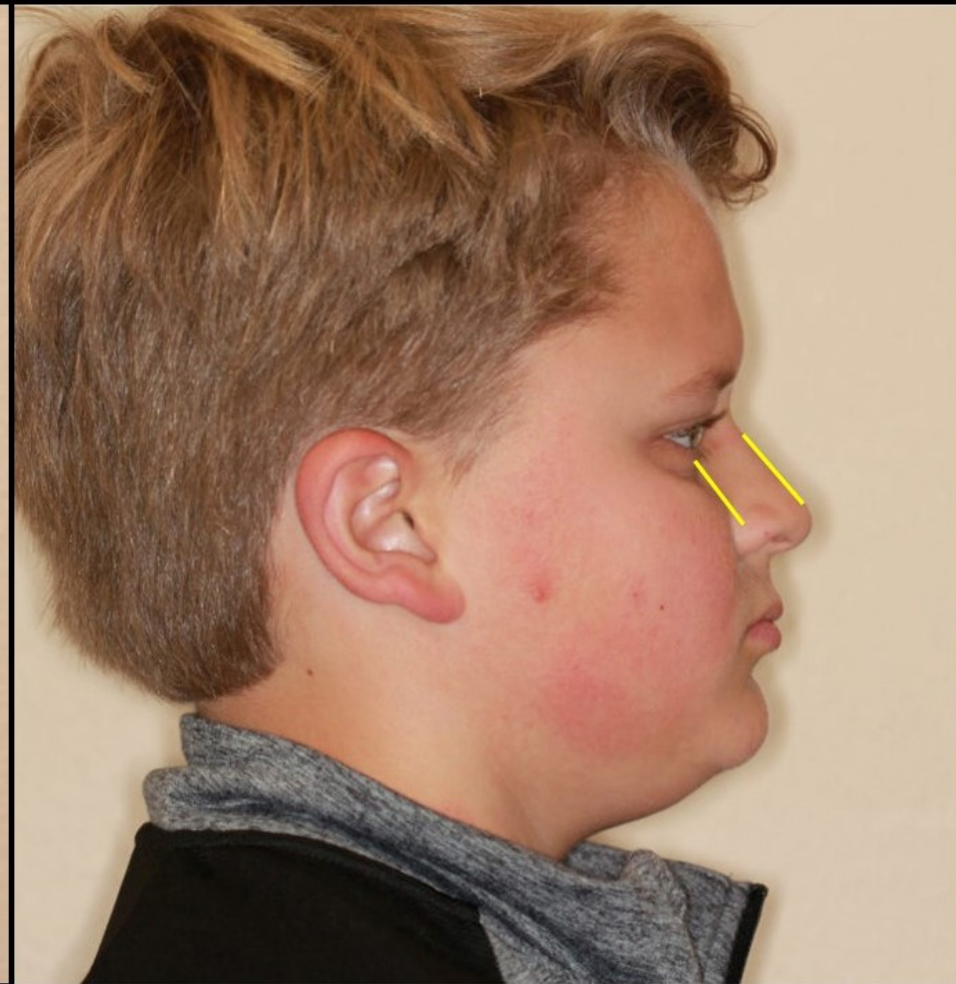
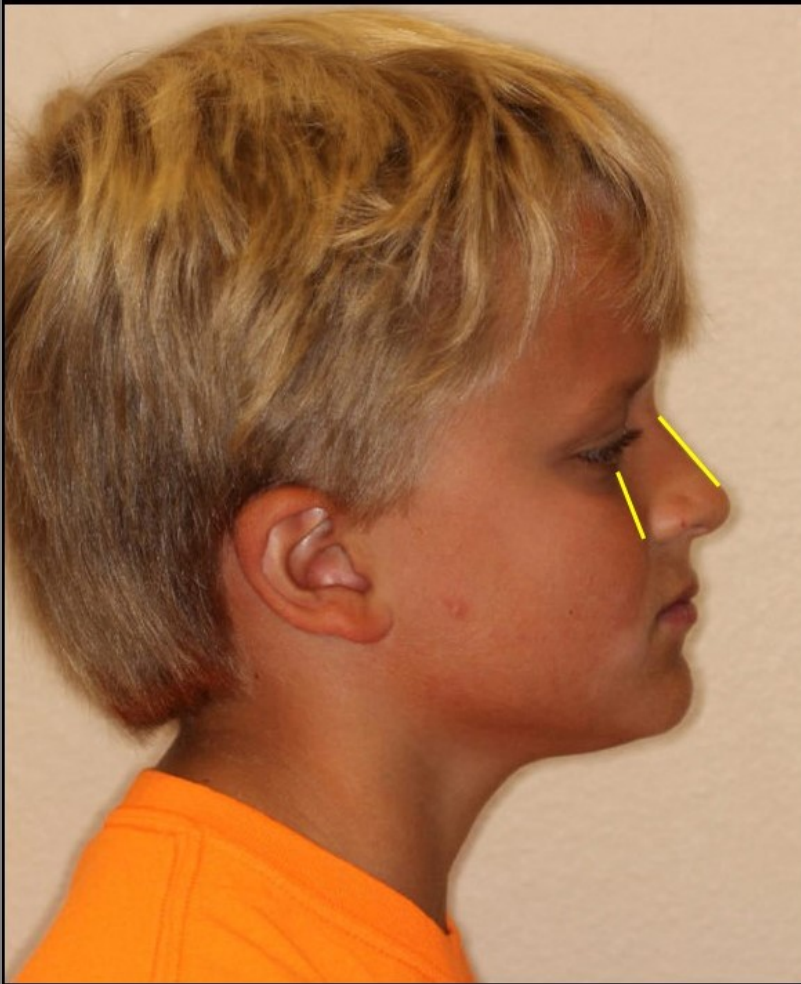


LR cuspid impacted horizontally in the chin which alters the finished occlusion.



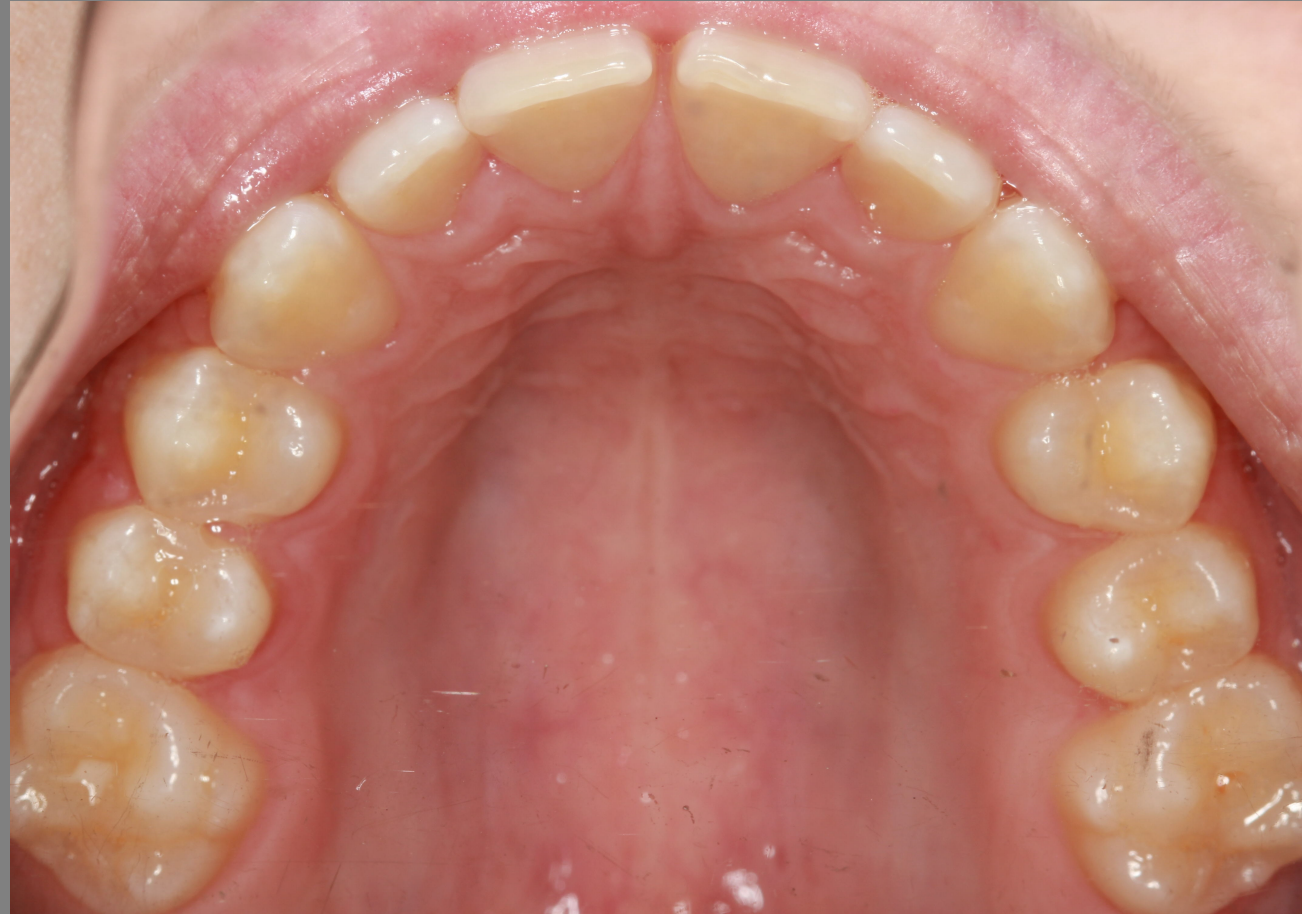



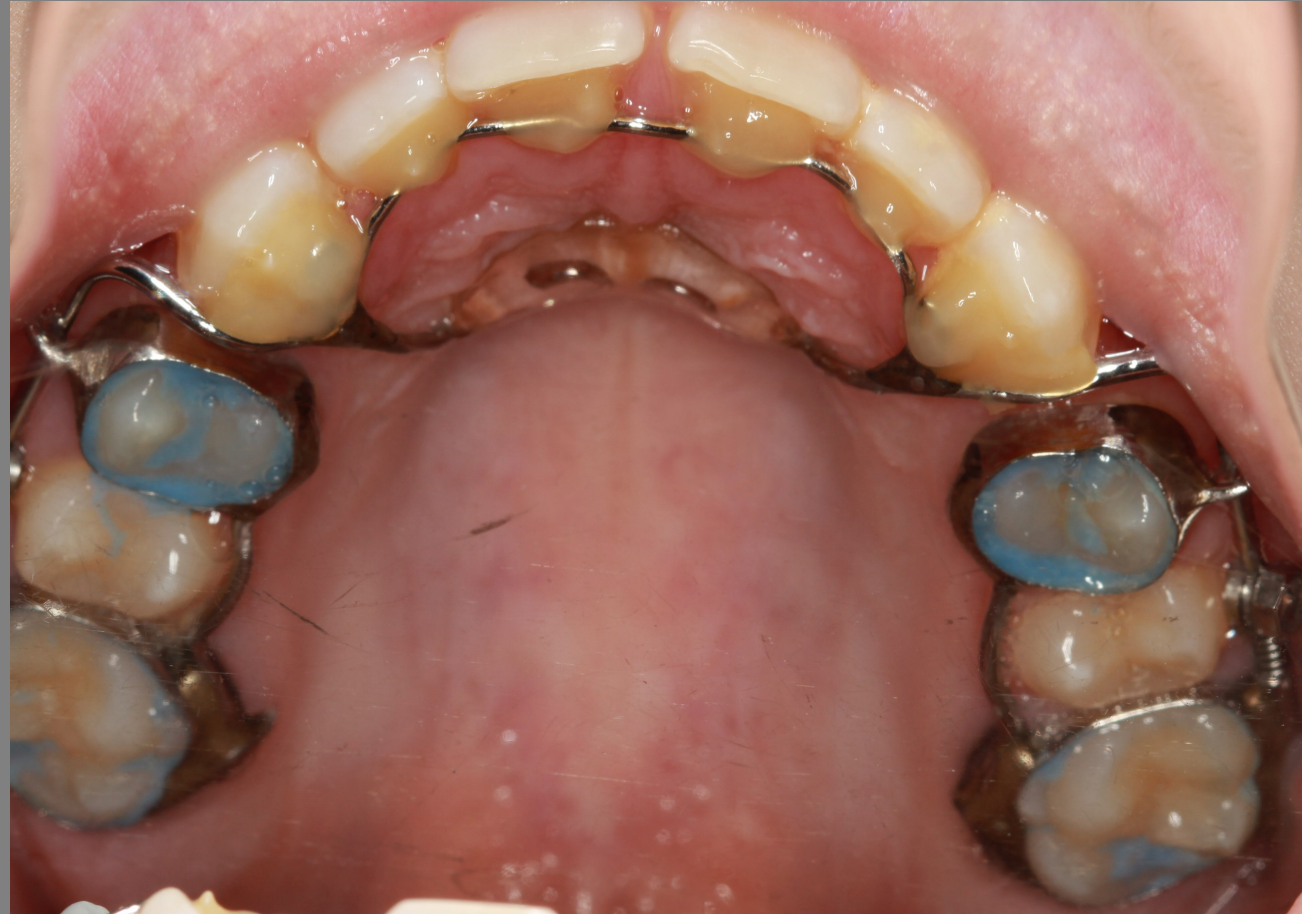Controlled Arch Orthodontics

Protraction Mechanics

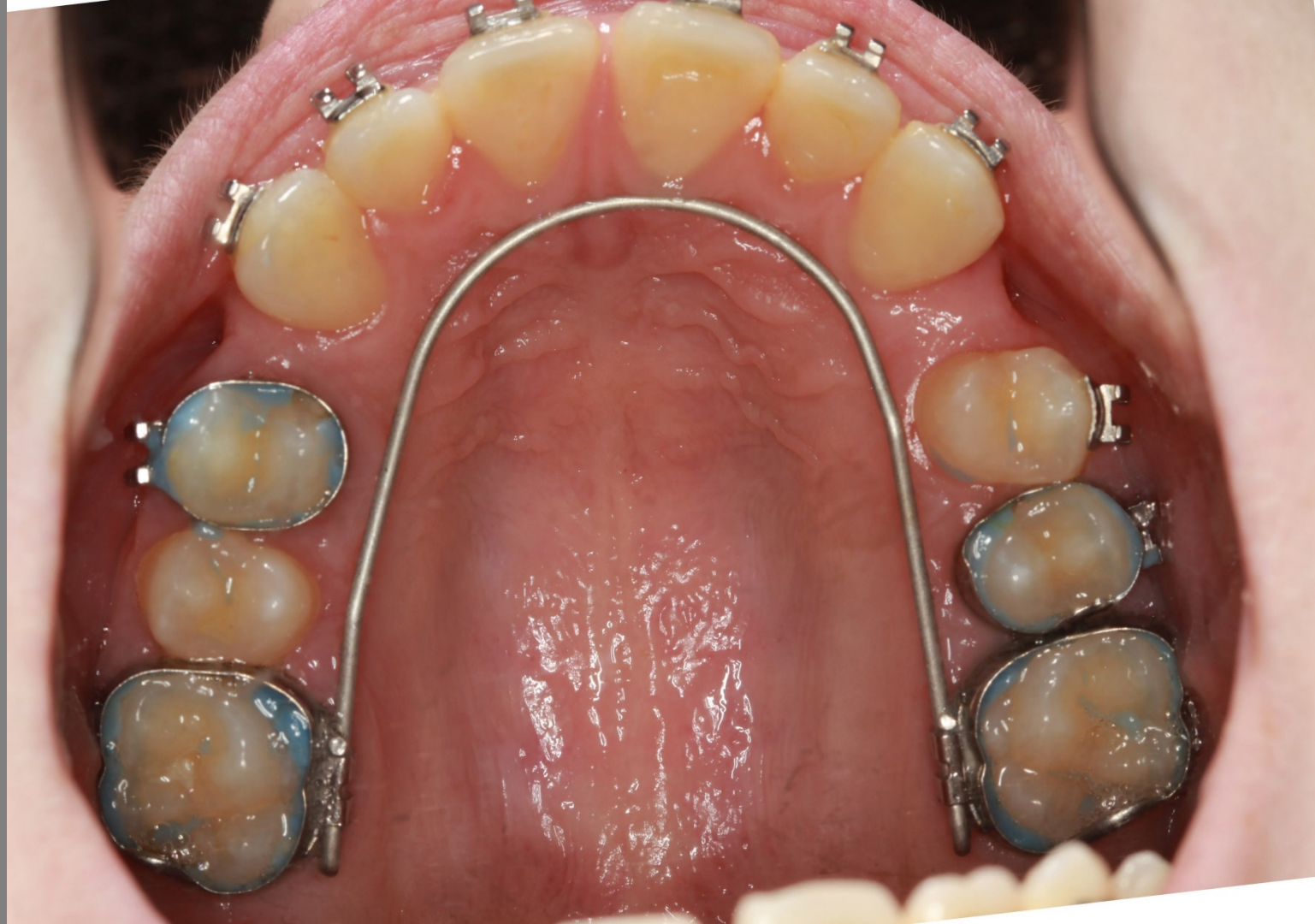Initial. Previous ortho. Diastema relapse
due to tongue



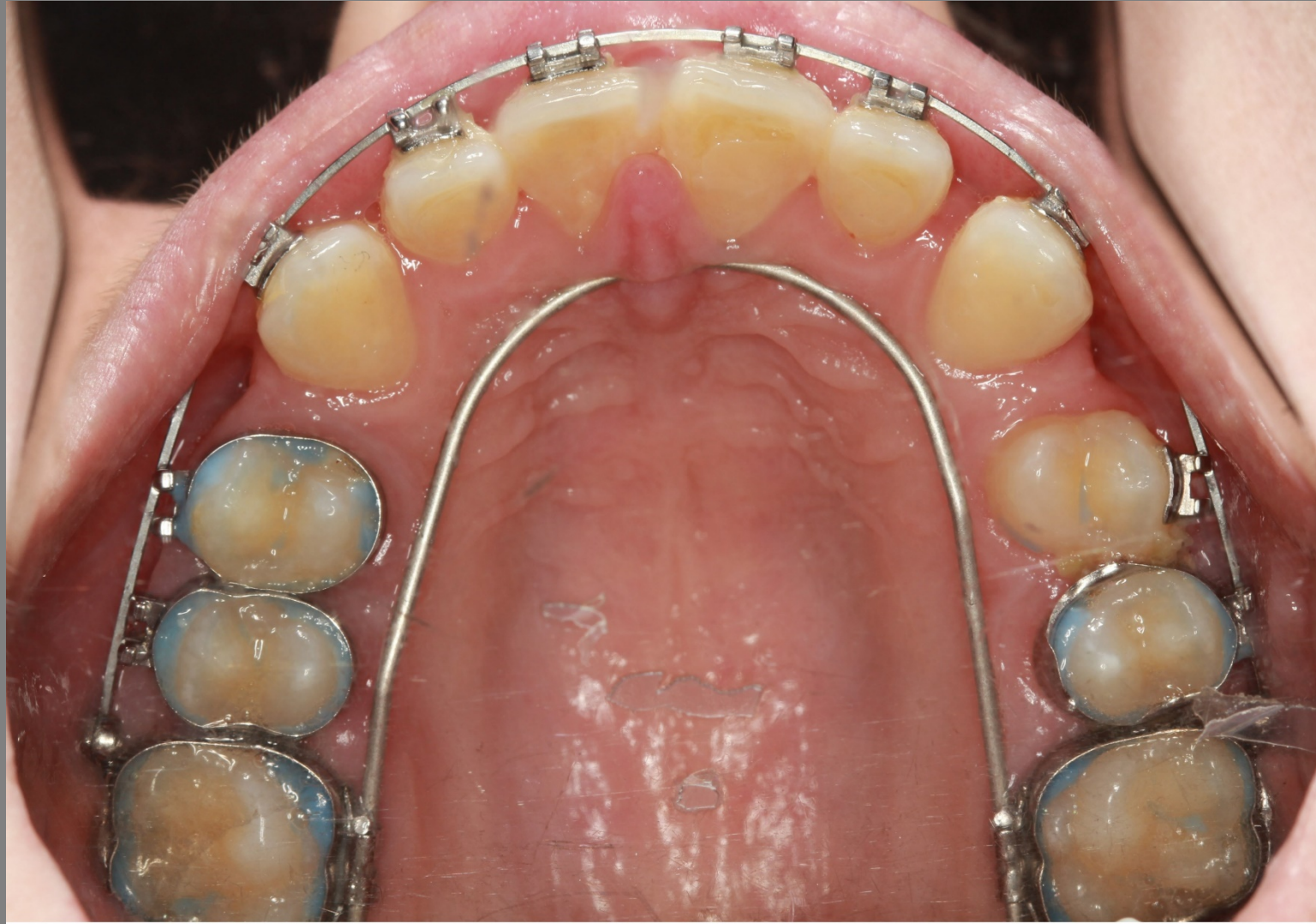Maxillary development with Fixed Guided Growth Appliance (FGGA)



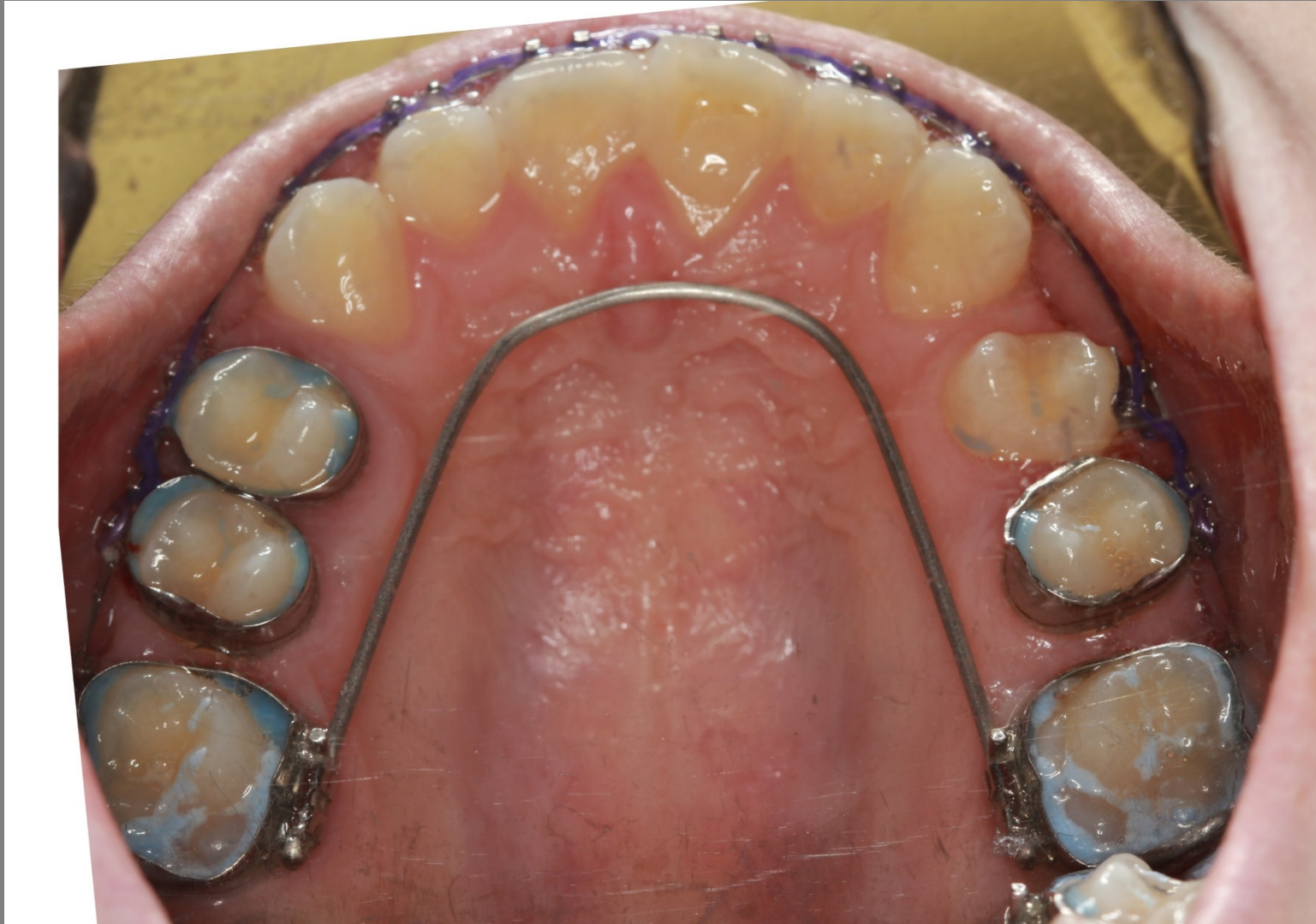Controlled Arch Initial



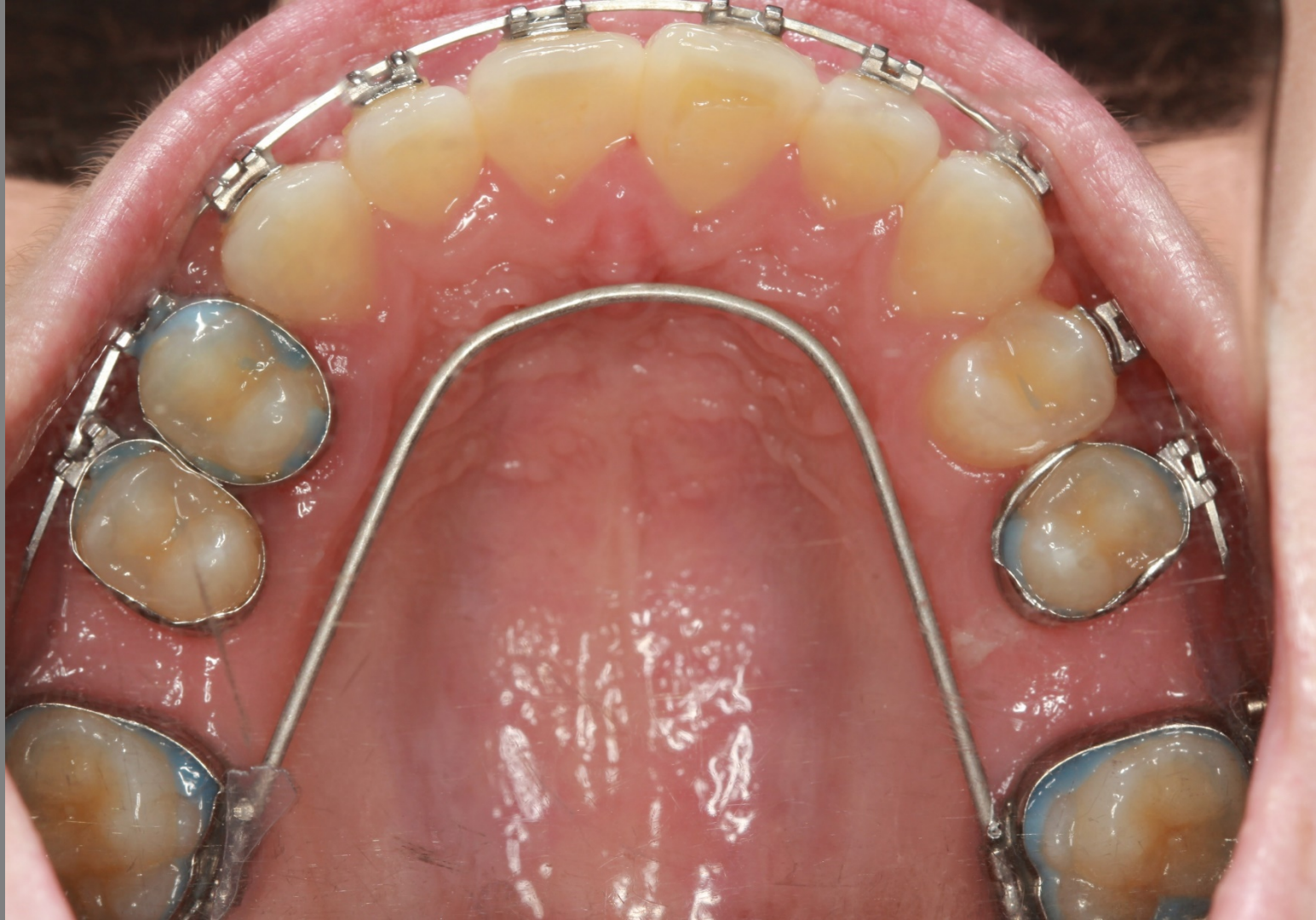Midline correction



Canine Protraction



Premolar Protraction



Molar Protraction

